

## Giant Epiglottic Cyst as Endoscopic Finding in Gastroscopy in A Patient with Retrosternal Heartburn, Dysphagia and Dysphonia

**Christos Sotiropoulos\***, Georgios Theocharis and Konstantinos Thomopoulos

Department of Gastroenterology and Hepatology, University General Hospital of Patras, Greece.

**\*Corresponding author:** Christos Sotiropoulos, Department of Gastroenterology and Hepatology, University General Hospital of Patras, Greece.

**Citation of this article:** Christos Sotiropoulos, Georgios Theocharis and Konstantinos Thomopoulos. (2026) "Giant Epiglottic Cyst as Endoscopic Finding in Gastroscopy in A Patient with Retrosternal Heartburn, Dysphagia and Dysphonia." *Archives of Medical Case Reports and Case Series*. 1(1). **Doi:** AMCRCS.CR.26.003

**Submitted:** April 07, 2026

**Accepted:** April 13, 2026

**Published:** April 16, 2026

### **Abstract:**

An epiglottic cyst is a cystic mass containing clear and uncontaminated fluid and is formed due to obstruction of the excretory duct of a submucosal gland, causing mucus to accumulate within it. Most epiglottic cysts are asymptomatic, but large cysts may cause a foreign body sensation in the throat, dysphonia, dysphagia, or dyspnea. Treatment options include aspiration of the cystic content, marsupialization of the cyst and complete excision.

**Keywords:** Dysphagia

### **Introduction:**

An epiglottic cyst is a cystic mass containing clear and uncontaminated fluid and is formed due to obstruction of the excretory duct of a submucosal gland, causing mucus to accumulate within it. Most epiglottic cysts are asymptomatic, but large cysts may cause a foreign body sensation in the throat, dysphonia, dysphagia, or dyspnea. Treatment options include aspiration of the cystic content, marsupialization of the cyst and complete excision.

### **Case report:**

A 40-year-old patient with a free medical history was referred to the gastroenterology department due to GERD symptoms for investigation and treatment. The patient reported postprandial retrosternal heartburn, since one year, with accompanying regurgitation, acid belching, dysphagia and dysphonia. The patient was initially prescribed an antisecretory drug for 8 weeks with partial remission of GERD symptoms, but with persistence of dysphagia and dysphonia. After performing a gastroscopy, a giant epiglottic cyst was revealed (Figure), while inspection of the upper digestive mucosa revealed grade A esophagitis according to Los Angeles. Continuation of antisecretory treatment and ENT assessment were recommended. The patient underwent a laryngoscopy and then a planned transoral resection of the cyst was performed, without complications. One month later the patient was re-evaluated by an ENT examination, without recurrence of the cyst and with remission of symptoms.

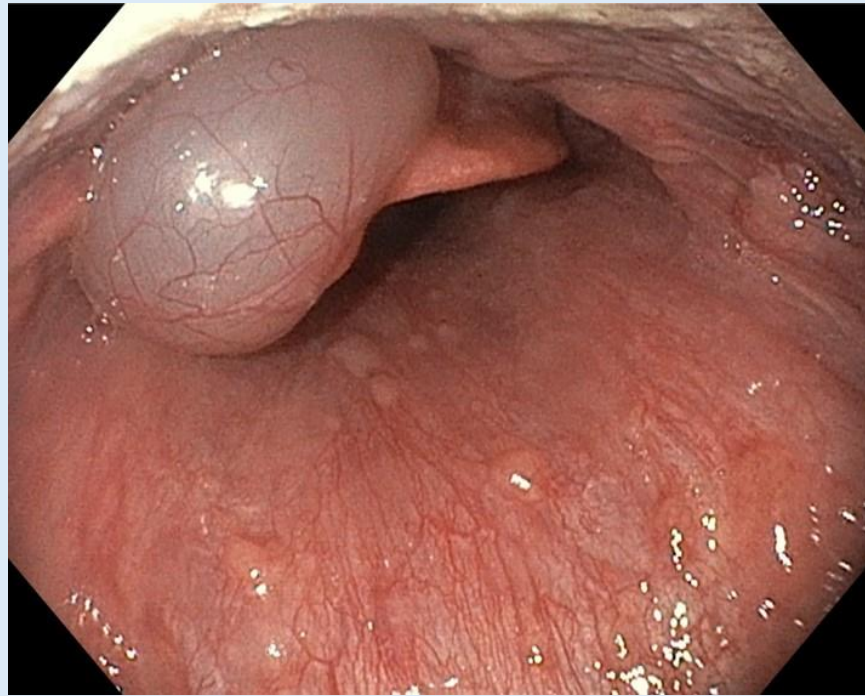


Figure. Giant epiglottic cyst.

### Conclusions:

Epiglottic cysts are rare and challenging when diagnosed incidentally by the endoscopist, while symptomatic cysts require immediate individualized management. The direct transoral approach for cyst excision is recommended as a safe and reliable method with a low recurrence rate.

### References

1. Ko SH, Sung ES. Large epiglottic cyst detected on videofluoroscopic swallowing study. *Lancet*. 2018 Jul 28;392(10144):311.
2. Ravichandran S, Subhashini PR, Raja K, Alexander A. Giant vallecular cyst: an impending threat for airway collapse. *BMJ Case Rep*. 2021 Jun 24;14(6):e244666.
3. Hasnaoui M, Masmoudi M, Chefai J, Hmida NB, Mighri K, Driss N. Le kyste de la vallécule symptomatique chez l'adulte: à propos de 4 cas [Symptomatic vallecular cyst in adults: about 4 cases]. *Pan Afr Med J*. 2018 Sep 18;31:36. French.
4. Singh J, Jain N, Jajoo M, Roy S, Narang E, Mahajan N. Varied Clinical Presentation and Management of Paediatric Vallecular Cyst. *Sultan Qaboos Univ Med J*. 2021 Nov;21(4):639-643.



©The Author(s) 2026. This article is an open access article distributed under the terms and conditions of the Creative Commons Attribution (CC BY) 4.0 License

#### Benefits of Publishing with us:

- ✓ fast; convenient online submission
- ✓ rigorous peer review by experienced research in your field
- ✓ rapid publication on acceptance
- ✓ authors retain copyrights
- ✓ unique DOI for all articles
- ✓ immediate; unrestricted online access

Click Here:

[Submit Manuscript](#)